

Minimizing injury to the donor area in follicular unit extraction (FUE) harvesting

Georgios Zontos, MD, BSc, MS, PhD,^{1,2} Ken L. Williams, Jr, DO,³ & George Nikiforidis, PhD²

¹Haarklinikken, Copenhagen, Denmark

²Department of Medical Physics, School of Medicine, University of Patras, Patras, Greece

³Family Medicine, Western University of Health Science, Pomona, CA, USA

Summary

Background Follicular Unit Extraction (FUE) is considered to be a minimally invasive procedure, and the injury to the donor area caused by a sharp punch may result in dermal fibrosis and clinically observed hypopigmentation.

Objective To evaluate with advanced image processing the efficacy of using 0.9% normal saline in minimizing the injury to the donor area in FUE donor harvesting.

Patients and methods The term acute extraction (AE) is used to describe the donor harvesting technique, whereby a follicular unit (FU) is removed with a punch that is aligned parallel with the exit angle of the hair follicle. The term vertical extraction (VE) describes the technique where a FU is removed in like manner, but normal saline is injected intradermally prior to harvesting so the punch being perpendicular to the skin. Thirty-five patients were selected for this study to apply both harvesting techniques and then to compare the differences in wound surface size and skin mass removed by the punch.

Results A significant reduction in the mean values of wound surface and skin mass was recorded in vertical extraction compared to those in acute extraction.

Conclusion The injection of normal saline prior to harvesting proved to be very efficient in minimizing skin injury in FUE harvesting.

Keywords: follicular unit extraction, hair transplant, injury to the donor area, image processing, normal saline, hypopigmentation

Introduction

Follicular Unit Extraction (FUE)^{1,2} is an emerging popular cosmetic hair restoration procedure to harvest hair follicles from the scalp donor area. Patient demand and recognition of this harvesting technique have increased significantly over the recent years. The

primary reason for FUE popularity is the minimally invasive nature of the technique and quick healing of the donor region.^{3,4} Another advantage of FUE is the harvesting method does not result in a donor linear scar that is associated with the strip harvesting method.

A potential disadvantage to FUE donor harvesting technique is the unaesthetic appearance of the donor area after extensive hair transplant procedures and donor depletion. In addition, to obtain a sufficient number of grafts, follicular units must also be extracted from the upper and lower portions of the mid-donor region which may not be as permanent. Over time,

Correspondence: Georgios Zontos, Medical Director of Haarklinikken, 1256 DK Copenhagen Denmark and Laboratory of Medical Physics, School of Medicine, University of Patras, 26504 Rio, Greece. E-mail: gdzontos@gmail.com

Accepted for publication July 25, 2016

because of the aging process, continued thinning in the upper and lower parts of the donor zone may cause the FUE scars to become visible.

Donor wound healing is related to hair and skin color variation with differing appearance in ethnic groups so that scarring to the donor area is more likely to occur. Therefore, clinically healing of the FUE wound may appear to the naked eye as multiple small white dots known as hypopigmentation⁵ when the hair is shaved or cut very short (Fig. 1). Early investigational studies by Cole⁶ and Rose⁷ reveal after the skin is scored with a sharp circular punch and the follicle is dissected and removed, the surgical donor wound surface area does not always correlate with healed wound size. For example, a 1.00-mm sharp circular punch may leave a scar that may be double in size. The increase in wound size has been suggested to be related to the lack of contractile forces when large numbers of punches are made in the harvesting area.

Increased scar formation or subdermal fibrosis from FUE wound healing is potentially an important cosmetic concern for the patients. Additionally for the physician, the resulting donor site fibrosis could make future FUE donor harvesting more challenging. It is generally believed the degree of scarring is directly related to the amount of donor area injury and depends on several factors, such as the total number of FUE procedures, the diameter of the circular sharp punch, the number of extracted follicular units (FUs) per cm,² the distance between the FUE entry sites, and

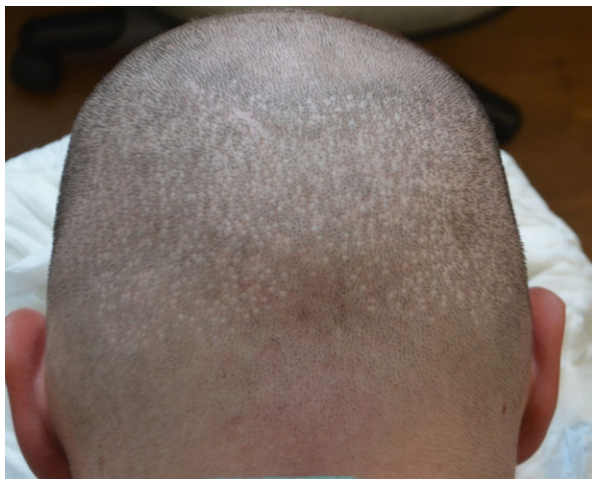

Figure 1 Numerous tiny scars, or punctate areas of hypopigmentation, are seen in the donor region in a patient with a short hair length (1 mm) (From Hair Transplant 360 Volume Four, with permission of Jaypee Brothers Medical Publishers).

the transection rate.⁸ The latter increases with acute angles of the exiting or emerging hair follicles and decreases with more perpendicular exiting hair angles.

The outgrowth angle^{9,10} or the exit angle of the follicle influences the injury to the donor area. A circular punch centered over the emerging hair follicle at an acute angle will produce an elliptical wound significantly larger in surface area than a punch harvesting a more perpendicular emerging hair shaft. To reduce the larger surface area of the wound, it has been suggested that 0.9% normal saline (NS) should be injected intradermally into the donor area, making the direction of the hair follicles more perpendicular so that the punch can be placed at a more obtuse angle.

After performing FUE with intradermal injections of normal saline, two consistent clinical observations were made. Firstly, the skin was stretched, so that the amount of skin mass removed per unit of cutting surface of the punch was much less than that removed from the skin that had not been injected with normal saline. Secondly, when normal saline had completely diffused or been absorbed by the tissues, the skin and dermal anatomy returned to normal. The dimensions of the wound surface were further reduced compared to the wound surface when normal saline was not used.

As healing in the donor region from FUE harvesting occurs by secondary intention,^{1,11} the size of wound and the amount of skin mass removed are two important factors that affect the healing process. Consequently, there are two ways by which a FU can be extracted from the donor area using a punch. One donor harvesting method uses a diluted lidocaine tumescent fluid for donor anesthesia. The circular sharp punch is then aligned parallel with the natural direction of the exiting hair follicle with subsequent scoring of the dermis, followed by dissection of the follicle from the primary surrounding follicular dermal attachments, that is, sebaceous gland and arrector pili muscle. The method described purposefully requires injection of 0.9% normal saline intradermally into the donor harvesting region so that the punch is directed at a more perpendicular angle or angle closer to 90°. The terms acute extraction (AE) and vertical extraction (VE) are introduced to describe the two donor harvesting methods, respectively.

Purpose

The purpose of this study was to assess the injury to the donor area when intradermal injections of normal saline are injected prior to donor harvesting.

Assessment of donor injury is mathematically calculated by three measurements:

- The exact percentage of skin mass in AE in comparison with VE.
- The average decrease in both skin mass removed and wound surface size in VE compared to AE 3 h after the follicle is extracted.
- The mean wound surface area in AE compared to VE.

Materials and methods

VE involves the injection of 0.9% normal saline into the dermis resulting in the skin volume expansion, while the density of skin mass contained in the same unit of volume decreases. A punch placed perpendicularly in tissue injected with normal saline results in a round or circular surface wound with a smaller volume and skin mass. When normal saline has diffused, the skin returns to its normal dimensions, and the volume of the wound becomes smaller. In comparison, in an AE, the same circular round punch is placed at more acute angle and results in a larger elliptical wound and the removal of additional tissue mass. Scoring and dissection of the entire length of the hair follicle potentially increase graft injury when using sharp punches for donor harvesting. A minimal penetration depth of the follicle to successfully score, dissect, and remove it is used, so the subcutaneous scalp fat layer does not play an important role in our study.

Our observations conclude that with AE, after successful removal of a follicle, the anatomy of the tissues around punch does not change, so the dimensions of the wound remain the same. However, the anesthetic or tumescent solution as well as edema caused by the trauma may have some effects on the wound volume.⁷

In both AE and VE, the grafts were extracted from the occipital area of the head following one out of every five FUs limiting the likelihood of causing a large number of FUE entry sites.

Quantifying the donor wound size and appearance after AE and VE requires a mathematical formula that measures the tissue mass removed in VE and the tissue mass removed in AE. Figure 2 demonstrates the cylinder of the punch cutting the skin to a certain depth while forming angle z .

Applying physics and trigonometry, the following formula was found:

$$m_A = \frac{1}{\sin^2 z} \times \frac{S_V}{S_A} \times m_V \quad (1)$$

where m_A is the mass of skin removed in AE, m_V the mass removed in VE, S_V the surface size of the wound when NS has completely diffused in VE and S_A the surface of wound in AE.

From equation (1), tissue damage occurs in AE is inversely proportional to $\sin^2 z$. This reveals a dramatic increase in trauma at small angles z , if normal saline is not used.

The function $f(z) = \frac{1}{\sin^2 z}$ shows that the value of m_A drops rapidly when z gets close to 90° .¹²

In equation (1), careful analysis reveals the ratio $\frac{m_A}{m_V}$ can be calculated if the surfaces of the wounds and the value of the angle z are measured. The value of angle z can easily be calculated with the formula

$$S_2 = \frac{S_1}{\sin z} \quad (2)$$

where S_2 is the initial wound in AE, and S_1 the cross section of the punch. Because the punch has a certain thickness, the outer diameter was measured with a digital micrometer and found to be (for the punches

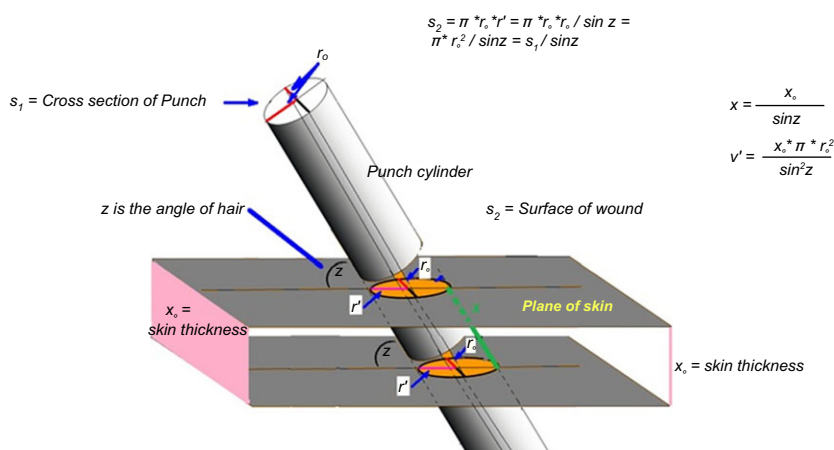


Figure 2 The diagram shows the cylinder of the punch as it cuts the skin to a certain depth x while forming angle z .

we use) at 1.111 mm. This diameter corresponds to 0.968 mm².

Thus, from equation 2 $\rightarrow z = \sin^{-1}\left(\frac{0.968}{S_2}\right)$

Clinically observed when performing VE is a reduction of the follicular transection rate in subsequent donor harvesting procedures. Further studies are required to draw any inferences that a decrease in transection rate is a result of reducing scar formation.

Protocol

Thirty-Five (35) patients were accepted into the study between the ages of 23–49 who underwent a routine hair restoration procedure. All patients underwent hair transplantation using the FUE donor harvesting method. The donor region was anesthetized with 0.5% lidocaine with 1:200 000 epinephrine that was injected subcutaneously rather than superficially. A sharp circular 1.0-mm punch (inner diameter) was used to harvest the donor area. An intact FU was extracted from the occipital region of the head, and using a high-resolution USB camera, microphotographs were taken of the surface of the wound immediately after the extraction. At a distance of 2 cm from the first wound, 0.3 mL of 0.9% normal saline was injected intradermally with a 30-G needle into a 1 cm² donor area to make the hair follicle more perpendicular. An intact FU was then extracted, and the same camera was used to take microphotographs of the wound. After 3 h, microphotographs were taken of each wound when normal saline had completely diffused.

Statistical analysis and image processing

In conjunction with the Department of Medical Physics at our University, a proprietary designed image processing software¹³ was adapted to accurately measure the surface size of the wounds in AE and VE.

The results from the measurements were statistically processed to validate the authenticity of our claim. The analysis was performed using SPSS version 19. Statistical differences were considered significant at $P < 0.05$.

Results

The results are shown in Table 1. SAE₁ and SAE₂ are the surface size of the same wound in AE immediately and 3 h after extraction. Similarly, SVE₁ and SVE₂ are the surface sizes of the same wound in VE. In general, the relative difference of a size is expressed by the ratio

$$\frac{\text{Final value} - \text{Initial value}}{\text{Initial value}} \times 100\%. \quad (3)$$

The percentage decrease in wound surface in AE and VE was determined with the help of this formula. The surface of each wound and the relative differences were calculated with the software. Both pictures of the same wound taken within a 3-h time interval were juxtaposed as shown in Figures 3 and 4.

Although in vertical extraction we made an effort a 1.00-mm punch to be placed perpendicularly to the surface of the skin, the shape of the wound was elliptical in appearance rather than circular as seen in Figure 5.

This small deviation was common in many of the sample microphotographs probably secondary to punch sliding, friction between the punch and skin surface, and the oblique angle of hair follicles. Similarly, this may be due to the surgeon exerting tension along one axis while entering the skin with the punch.

Immediately after the extraction, the mean value of wound surface in both AE and VE was 1.39 mm² ± 0.15 and 1.07 mm² ± 0.10, respectively. Three hours later, these values became 1.27 mm² ± 0.19 and 0.69 mm² ± 0.11, showing a significant decrease in wound surface in VE.

Table 2 shows that the mean relative difference of wound surface in AE was -9.10% ± 6.58, whereas in VE, it was -35.49% ± 9.52. Therefore, if the donor area was tumesced and an elliptical approach was taken, it is assumed the volume is less than that in a nontumesced donor region.

In order to successfully compare the wound surface size in AE with that in VE, we calculated the relative difference of (SAE₂-SVE₂)/SVE₂ between the surface of the final wounds in AE and VE, respectively. When normal saline had completely diffused, the relative differences ranged from 24.69% to 159.68%. Combining the relative differences for all patients resulted in an overall comparative difference of 87% ± 27%. This value reflects the average wound surface in AE is 87% larger than in VE.

Moreover, the angle between the punch and the skin surface in AE was calculated for each case. The angle range was from 33.37° to 55.83°, and the mean value was 45.07°. After calculating the angle z , the percentage of skin mass removed in AE compared to VE was determined as per equation (1). In Table 3, it is recorded that the average skin mass removed in AE was 395% ± 133 larger than in VE.

All the data are analyzed by applying independent sample t-test, and it was found that $P = 0.000 < 0.05$.

Table 1 The results from measurement of SAE₁, SAE₂, (SAE₂ - SAE₁) / SAE₁, angle, SVE₁, SVE₂, (SVE₂ - SVE₁) / SVE₁, Relative Mass and Relative Wound = (SAE₂-SVE₂) /SVE₂

SAE1 (mm ²)	SAE2 (mm ²)	(SAE2-SAE1)/ SAE1 (%)	Angle	SVE1 (mm ²)	SVE2 (mm ²)	(SVE2-SVE1)/ SVE1 (%)	Relative Mass (%)	Relative Wound (%)
1.30	1.06	-18.46	48.13	1.02	0.49	-51.96	390.16	116.33
1.50	1.45	-3.33	40.19	1.04	0.81	-22.12	429.85	79.01
1.63	1.62	-0.61	36.43	1.28	0.86	-32.81	534.12	88.37
1.31	1.14	-12.98	47.64	1.19	0.69	-42.02	302.59	65.22
1.26	0.96	-23.81	50.20	0.99	0.57	-42.42	285.36	68.42
1.18	1.11	-5.93	55.12	0.97	0.59	-39.18	279.57	88.14
1.54	1.53	-0.65	38.94	1.22	0.66	-45.90	586.73	131.82
1.52	1.45	-4.61	39.56	1.05	0.84	-20.00	425.62	72.62
1.73	1.60	-7.51	34.02	1.25	0.75	-40.00	681.40	113.33
1.25	1.20	-4.00	50.75	1.02	0.72	-29.41	277.92	66.67
1.30	1.06	-18.46	48.13	1.00	0.70	-30.00	273.11	51.43
1.23	0.85	-30.89	51.91	1.08	0.39	-63.89	351.90	117.95
1.37	1.24	-9.49	44.96	1.05	0.63	-40.00	394.25	96.83
1.30	1.19	-8.46	48.13	1.08	0.82	-24.07	261.74	45.12
1.39	1.22	-12.23	44.14	1.19	0.83	-30.25	303.08	46.99
1.51	1.47	-2.65	39.87	1.09	0.82	-24.77	436.22	79.27
1.23	1.17	-4.88	51.91	1.15	0.57	-50.43	331.41	105.26
1.20	1.09	-9.17	53.77	1.06	0.67	-36.79	250.01	62.69
1.31	1.12	-14.50	47.64	1.06	0.57	-46.23	359.86	96.49
1.37	1.25	-8.76	44.96	1.07	0.73	-31.78	342.99	71.23
1.34	1.27	-5.22	46.25	1.02	0.68	-33.33	357.89	86.76
1.34	1.32	-1.49	46.25	0.96	0.76	-20.83	332.83	73.68
1.43	1.38	-3.50	42.60	1.14	0.74	-35.09	406.98	86.49
1.58	1.34	-15.19	37.78	0.98	0.67	-31.63	532.84	100.00
1.37	1.24	-9.49	44.96	1.00	0.69	-31.00	359.97	79.71
1.26	1.19	-5.56	50.20	1.00	0.66	-34.00	305.49	80.30
1.28	1.20	-6.25	49.13	1.06	0.58	-45.28	361.76	106.90
1.49	1.33	-10.74	40.52	0.96	0.64	-33.33	492.37	107.81
1.54	1.45	-5.84	38.94	1.07	0.70	-34.58	524.28	107.14
1.26	1.22	-3.17	50.20	1.02	0.59	-42.16	350.35	106.78
1.59	1.50	-5.66	37.50	1.17	0.77	-34.19	525.59	94.81
1.17	1.01	-13.68	55.83	1.06	0.81	-23.58	182.16	24.69
1.45	1.28	-11.72	41.88	1.20	0.88	-26.67	326.37	45.45
1.35	1.20	-11.11	45.81	0.93	0.58	-37.63	402.41	106.90
1.76	1.61	-8.52	33.37	0.95	0.62	-34.74	858.44	159.68

There is a statistically significant difference between the means with a 95% confidence interval of the difference.

Discussion

Unger¹⁴ described one method to calculate trauma or scarring to the donor area caused by both the FUE and strip harvesting method. He defined donor site trauma as the total donor linear scar incision length. Harris¹⁵ suggested an alternative assessment method by measuring the total volume of tissue removed. For example, Harris calculated that a 500 FUE graft procedure produces donor scarring that is 20% less than a strip harvesting technique removing the equivalent number of follicular units.

Harris' calculations assumed the volume of the tissue removed by the punch is equal to the volume of the

cylinder of the punch directed perpendicularly to the surface of the skin. This assumption is correct for VE.

Mathematical models and modern technology reveal trauma or scarring to the donor area can be calculated precisely by measuring the volume of tissue mass removed by the circular sharp punch. Considering that the depth of tissue is the same in both acute extraction and vertical extraction, in AE, the final mean volume of the wound is 87% larger than the final volume of the wound in VE, while the mean mass of tissue extracted in AE is 394% more than that in VE.

However, if we do not take into consideration the effects of normal saline, then the values could be far less. For example, if the angle of 1.00-mm punch is at 47° with the skin, then the volume of the punch cylinder, when the penetration depth is 4 mm, is 4.4 mm³. Similarly, if the same size punch is placed

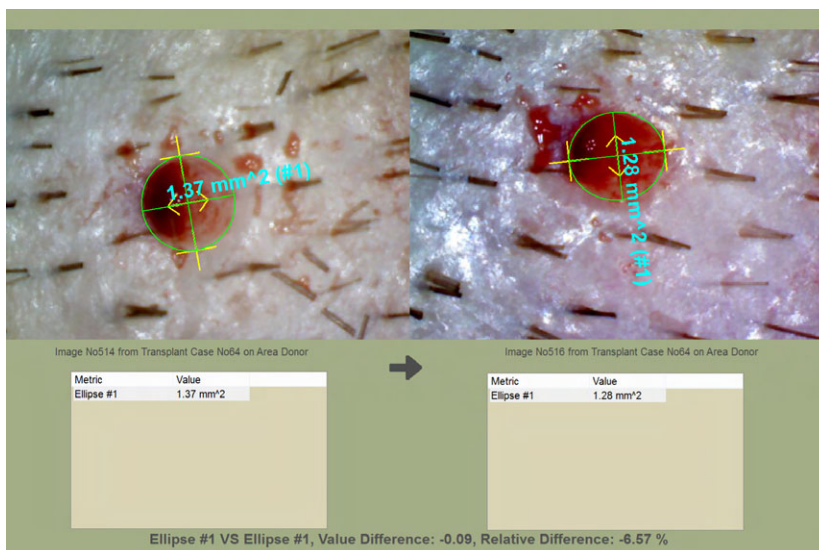


Figure 3 Automatic comparison of the surface of the same wound in AE immediately and 3 h later using the advanced image processing reveals a 6.57% decrease in surface of the wound (Proscope HR2 digital micro picture, magnification 50).

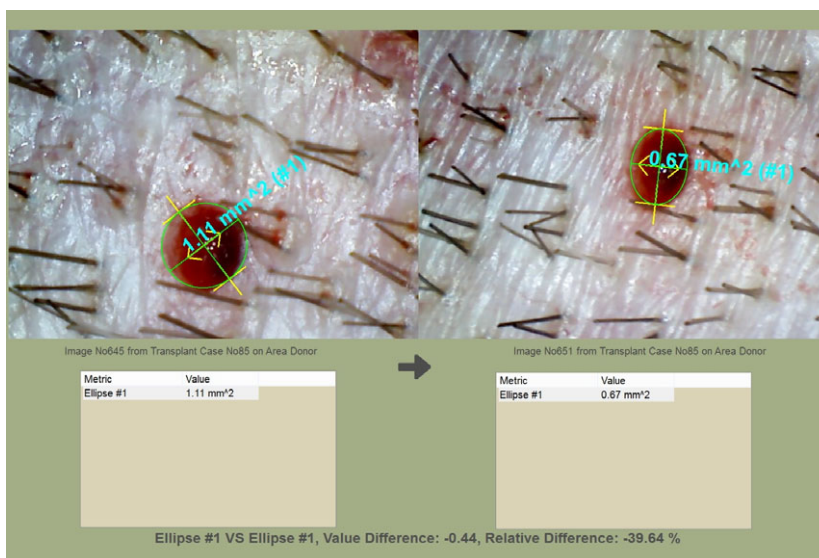


Figure 4 After 3 h, the surface of the wound in VE decreases by 39.64% (Proscope HR2 digital micro picture, magnification 50).

perpendicularly (without injecting normal saline), the corresponding value could be 3.14 mm^3 . The increase in wound volume is only 25%. Therefore, the marked differences in mass and wound volume are both associated with the intradermal injection of normal saline and the angle of the punch.

The statistical analysis of the results demonstrates the standard deviation of the mean values of the percentage of mass removed and that of wound surface in

acute extraction is relatively high. An explanation of this finding may be secondary to the varying viscoelastic properties of skin¹⁶ from one person to another depending on age, sex, thickness of skin, and the number of previous hair transplant procedures.

Patients with extensive scarring in the donor area from previous hair transplantation procedures characteristically have less skin elasticity than patients who have not previously undergone a hair transplantation




Figure 5 The microphotograph (Proscope HR2 digital micro picture, magnification 50) illustrates the elliptical shape of the wound right after the application of VE.

Table 2 Mean values of SAE₁, SAE₂, (SAE₂ – SAE₁) / SAE₁, SVE₁, SVE₂, (SVE₂–SVE₁)/SVE₁.

	SAE1 (mm ²)	SAE2 (mm ²)	(SAE2 –SAE1/ SAE1	SVE1 (mm ²)	SVE2 (mm ²)	(SVE2 –SVE1)/ SVE1
Mean	1.39	1.27	–9.10%	1.07	0.69	–35.49%
SD	0.15	0.19	6.58	0.10	0.11	9.52

Table 3 Mean values of the percentage of sizes of Relative Mass and relative wound

	Relative Mass (%)	Relative Wound (%)
Mean Values	395	87
SD	133	27

procedure. It is reasonable to assume by injecting intradermally the same amount of normal saline per cm² of donor area, the stretching of the skin would be greater in the untouched virgin scalp than patients with previous hair surgery. After removal of the intact FU and following the diffusion and absorption of normal saline, the skin contraction is much greater in the virgin untouched scalp. The effect of VE on the remaining wound is a significantly smaller wound size. At the same time, the total tissue mass removed by the punch is reduced, which further minimizes the injury to the donor area.

In our study, we analyzed the results from other similar cases to those described above. In a 49-year-old patient who had already undergone 3 strip procedures, the wound size in VE had decreased by 23%, the

Table 4 Two characteristic clinical cases

Age	Previous procedures	(SVE2–SVE1)/ SVE1 (%)	Relative Wound (%)	Relative Mass (%)
49	3	23	24.69	49.38
23	0	34.74	139.68	858.44

relative difference between the final wound in AE and VE was 24.69%, and the mass removed in AE was 49% more than in VE. However, in a younger patient without previous hair surgery, the wound size in VE had decreased by 34.7%, the relative difference between the final wound in AE and VE was 139%, and the mass removed in AE was 858% more than in VE (Table 4).

As a consequence of the inability of the skin to readily expand by the intradermal injection of normal saline in patients with donor scarring, these findings imply that VE has more positive effects on patients with less scarring in the donor area, when compared to patients who have extensive scarring from the previous scalp procedures.

In FUE donor harvesting, it is important to recognize the anatomical phenomenon of follicle splaying to be successful in harvesting follicles. Splaying of the follicle probably increases the transection of the lower portion of the hair follicle while scoring the dermis and dissecting the follicle from the dermal attachments. Rose⁷ proposed the follicle exit angle can differ from the internal angle of the hair that likely results in higher harvesting transection rate, particularly in patients with very wavy or curly hair. While not objectively analyzed, it is believed by the authors that intradermal injection of normal saline makes the hair follicles, within the same follicular unit, more vertical and potentially reduces follicular hair splaying.

In our opinion, N/S injection prior to harvesting has minimum or no effect on harvesting from very curly follicular units. In this case, the increase in punch size may improve the extraction, but causes a larger wound.

FUE donor harvesting in subsequent FUE sessions may be associated with technical difficulties such as high transection and low harvesting rates. The hypothesis in this study is that extensive scar formation or fibrosis in the donor region results in increased friction forces exerted by the punch when in contact with the skin's surface. This potentially causes follicular displacement and a greater potential for higher transection rates. Higher transection rates can result in

further injury to the donor area. Theoretically, with an increase in a greater number of harvesting attempts to obtain the desired number of grafts, scar formation or wound fibrosis is increased. Moreover, because the scarring on the donor area has an additive effect, the necessity of decreasing the injury to the donor area becomes a priority.

The methodology and concepts introduced and discussed add to the idea that normal saline injections prior to donor harvesting results in decreased tissue injury to the donor region. Additionally, in VE, less tissue damage potentially makes the probability of severing the underlying vessels less likely, minimizing bleeding and other rare complications such as skin necrosis.¹⁷ Based on the principle that an increase in donor trauma results in a higher degree of scarring, we believe vertical extraction in FUE limits scar formation, lowers transection, and increases harvesting rates in subsequent FUE procedures.

Normal saline injections into the skin and dermis cause the skin turgor to increase and assist the downward motion of the punch in scoring the dermis and tissue dissection of the follicle from the surrounding dermal tissues. The desired outcome of FUE donor harvesting is the successful extraction of intact follicular units. Although the injury to the skin and the scar formation are minimal, the total removal of a FU leads to the absence of pigmentation in the skin. This mechanism could be an explanation why hypopigmentation does not decrease when using VE.

It is commonly accepted within the medical community that donor hypopigmentation is directly related to wound scarring. Therefore, it could be theorized that limiting fibrosis and scarring in the donor area would reduce the hypopigmentation effect. Nevertheless, in our opinion, apart from scarring, hypopigmentation is also associated with the deficit of melanocytes¹⁸ from the harvested follicle in the donor wound.⁹

Conclusion

In this study, we evaluated the efficacy of intradermal injection of normal saline to reduce the donor region scarring by FUE harvesting. The application of mathematical equations and modeling validated its value by accurately measuring the reduction in skin wound in VE with the help of advanced proprietary image processing and comparing it with the reduction of skin wound in the AE control group. Even though the 3-h time interval between the measurements was chosen so that normal saline would have completely diffused, before the inflammatory process could become

manifest, the wound in AE was unexpectedly reduced by a mere 9%. This effect was mainly produced by acute trauma and the accompanying edema.

The discussion of reduced donor scarring and fibrosis by vertical extraction of follicles emphasizes the important role of intradermal injection of normal saline prior to FUE donor harvesting. In addition, VE has been thoroughly described and explained, demonstrating that both physician and patient can benefit from its application during an FUE procedure. Ultimately, VE minimizes injury to the donor area, while allowing for an easier and more efficient extraction.

References

- 1 Rassman W, Bernstein R, McClellan R *et al*. Follicular unit extraction: minimally invasive surgery for hair transplantation. *Dermatol Surg* 2002; **28**: 720–8.
- 2 Rassman W, Harris JA, Bernstein RM. Follicular Unit Extraction. In: Haber RS, Stough DB eds. *Hair Transplantation*. Philadelphia: Elsevier Saunders, 2006: 133–7.
- 3 Ken L, Williams Jr. Current practices and controversies in cosmetic hair restoration. *Dermatol Surg* 2013; **39**: 798–801.
- 4 Avram M, Rogers N. Contemporary hair transplantation. *Dermatol Surg* November 2009; **35**: 1705–19.
- 5 Boden S, Williams K. Motorized FUE with sharp punch. In: S Lam, K Williams, eds. *Hair Transplant 360 Follicular Unit Extraction (FUE)*, vol. 4, 1st edn, Philadelphia, PA: Jaypee Medical Publishers Inc.; 2016; Ch. 16, pp. 284–9.
- 6 Cole JP. An analysis of follicular punches, mechanics, and dynamics in follicular unit extraction. *Facial Plast Surg Clin North Am* 2013; **21**: 437–47.
- 7 Rose P. Internal Angle of Hair Growth versus Exit Angle as it relates to FIT/FUE, Presented International Society Of Hair Restoration Surgery Annual Meeting 2010, Boston, MA.7
- 8 Harris JA. New methodology and instrumentation for follicular unit extraction: lower follicle transection and expanded patient candidacy. *Dermatol Surg* 2006; **32**: 56–62.
- 9 Zontos G, Rose P, Nikiforidis G. A mathematical proof of how the outgrowth angle of hair follicles influences the injury to the donor area in FUE harvesting. *Dermatol Surg* 2014; **40**: 1147–50.
- 10 Zontos G. *The Physics of follicular unit extraction*. In: S Lam, K Williams, eds. *Hair Transplant 360 Follicular Unit Extraction (FUE)*, 1st edn, Philadelphia, PA: Jaypee Medical Publishers Inc.; 2016; pp. 45–68.
- 11 Zabel D. Wound healing. In: L Way, G Doherty, eds. *Current Surgical Diagnosis and Treatment*, 11th edn, New York: McGraw-Hill; 2003; pp. 86–99.
- 12 Ayres F, Moyer RE. TRIGONOMETRY: Schaum's outline series. New York: McGraw-Hill, 1998.

- 13 Gonzalez RC, Woods RE, Eddins SL. *Digital Image Processing Using MATLAB*, 2nd edn. Knoxville, TN: Gatesmark Publishing; 2009.
- 14 Unger W. Commentary. *Dermatol Surg* 2006; **32** : 61–2.
- 15 Harris J, In A. Response to commentary on new methodology and instrumentation for follicular unit extraction: lower follicle transection rates and expanded. *Dermatol Surg* 2006; **32** : 599.
- 16 Silver FH, Freeman JW, DeVore D. Viscoelastic properties of human skin and processed dermis. *Skin Res Technol* 2001; **7** : 18–23.
- 17 Karaçal N, Uraloğlu M, Dindar T. Necrosis of the donor site after hair restoration with follicular unit extraction (FUE): a case report. *J Plast Reconstr Aesthet Surg* 2011; **65**: e87–9.
- 18 Kim SR, Han KD, Kim CY. Repigmentation of Vitiligo using the Follicular unit extraction technique. *Dermatol Surg* 2014; **40** : 1425–7.